

EFFECT OF A PHYTOTHERAPY OIL PREPARATION UPON THE CUTANEOUS ERYTHEMA

EFFECTUL UNUI PREPARAT FITOTERAPIC ULEIOS ASUPRA ERITEMULUI CUTANAT

ANDRÎTOIU C.V.¹, PRISĂCARU Anca Irina¹, ANDRIESCU Corina², POPA I.M.¹

e-mail: dr_calin_andritoIU@yahoo.com

Abstract. Cutaneous erythema appears frequently as a reaction of immune-sensitization due to industrialization and pollution, use of chemical substances for housekeeping, use of body care products. The present experiment evaluates the efficiency of a topical treatment of cutaneous chemically induced erythema in Wistar rats, using a phytotherapy oil preparation. The experimental model was achieved with 85% aqueous solution of lactic acid. The preparation used to treat the cutaneous lesions for 7 days included: olive oil (*Oleum olivarum*), linseed oil (*Oleum lini*), corn oil (*Oleum maydis*), sea buckthorn oil (*Oleum Hippophaë*), grape seed oil. Macroscopic, clinical and histopathological evaluations were performed. The results emphasize the efficiency of oil preparation in cutaneous erythema, with evident improvements from the third day of treatment. In conclusion, the oil preparation may be used with good results in the treatment of cutaneous erythema, as it is biocompatible, and can be included in dermatology and cosmetic products.

Key words: *Oleum olivarum*, *Oleum lini*, *Oleum maydis*, *Oleum Hippophaë*, grape seed oil.

Rezumat. Eritemul cutanat apare frecvent ca reacție de imunosensibilizare, datorită industrializării și poluării, folosirii de substanțe chimice în gospodărie, utilizarea de produse de îngrijire corporală ce conțin compuși chimici de sinteză. Prezentul articol își propune evaluarea eficienței tratamentului topic a eritemului cutanat indus chimic la șobolani Wistar, utilizând un preparat fitoterapic uleios. Modelul experimental s-a realizat cu ajutorul unei soluții apoase de acid lactic 85%. Preparatul uleios folosit pentru tratarea leziunilor timp de șapte zile conține: ulei de măsline (*Oleum olivarum*), ulei de in (*Oleum lini*), ulei de porumb (*Oleum maydis*), ulei de cătină (*Oleum Hippophaë*), ulei de sămburi de struguri. S-au urmărit evaluarea macroscopică, clinică și histopatologică. Rezultatele evidențiază eficiența preparatului asupra eritemului cu rezultate clinice evidente încă din a treia zi de utilizare topică. În concluzie, preparatul fitoterapic uleios se poate folosi cu bune rezultate în tratamentul eritemului cutanat, fiind biocompatibil și se poate include în produse cosmetoterapice.

Cuvinte cheie: *Oleum olivarum*, *Oleum lini*, *Oleum maydis*, *Oleum Hippophaë*, grape seed oil.

¹ "Gheorghe Asachi" Technical University of Iași, Romania

² "Sf. Parascheva" Clinical Hospital of Infectious Diseases, Iași, Romania

INTRODUCTION

Skin is a complex organ, having as major role the protection against fluid loss (Merică, 2003) and represents a way of administration for dermatology and cosmetic products, the highest rate of absorption being held by the oil formulations (Cosmovici et al., 1980).

Olive oil has antioxidant properties due to phenols, protective effects against UV skin injuries (Ichihashi et al., 2003), antitumor activity due to the property of 3,4-dihydroxyphenyl-ethanol (3,4-DHPEA) to inhibit the cell proliferation by blocking the cell cycle in G0/G1 phase and to induce the apoptosis of the tumor cell line (HL60) (Fabiani et al., 2002).

The grape seed oil contains compounds with antioxidant activity and unsaponifiable lipids (β -sitosterol, campesterol, and stigmasterol), offering resistance against peroxidation. Thus, it is suitable as a cosmetic ingredient, in different formulations used in treating dry and aged skin, helps to regulate the skin pH, and has the attribute of being hypoallergenic (Sineiro et al., 1995).

Furthermore, the plant and seed oils contain phytohormones that stimulate the blood flow, accelerate the cell regeneration, and improve tonicity, acting with success upon aged skin. Corn oil is one of these oils, with a high content of vitamins E and F (Braha, 1998). The essential fatty acids maintain the hydration of the skin and prevent from atopic dermatitis, psoriasis, acne and eczema. More over, the active principles from the linseed oil act upon open wounds and skin burns (Ardelean et Mohan, 2008), also possessing emollient effect (Istodor, 1998). The sea buckthorn oil contains glycerides of fatty acids, carotenoid compounds and other lipid substances that offer this oil benefic effects upon cutaneous lesions (Grigorescu et al., 2001).

The present study aims to evaluate the efficiency of a topical oil preparation that contains a mixture of natural oils (olive oil - *Oleum olivarium*, linseed oil - *Oleum lini*, corn oil - *Oleum maydis*, sea buckthorn oil - *Oleum Hippophaë*, grape seed oil) in the treatment of cutaneous chemically induced erythema in Wistar rats.

MATERIAL AND METHOD

In order to demonstrate the reepithelization effect of the above mentioned oil preparation, the following experimental model of chemically induced erythema was achieved:

- female rats, Wistar strain, with a body weight comprised between 220-250 g, have been divided into 2 groups: non-treated group (group 1, with chemically induced erythema and non-treated), oil preparation group (group 2, with chemically induced erythema and treated with the natural oil preparation);
- the dorsal surface of the animals was shaved by mechanical and chemical methods (first, the hair was cut with a scissor; then an epilation cream was applied, according to the indications on the label of the product; consequently, the epilated area was rinsed with normal saline solution);
- the chemical erythema was induced by washing the two paravertebral areas of each rat with a 85% aqueous solution of lactic acid; the affected areas were left for 24 hours, without rinsing them with normal saline solution;

- after 24 hours, the laboratory animals were topically treated with the tested oil preparation for 7 days, until complete healing of the wound was ascertained; during these 7 days, macroscopic and clinical examinations were achieved;
- in the end, a specimen sample of tissue removed from the healed skin of all rats was taken with a 3 mm biopsy punch in order to be analyzed by histopathological examination. The collected samples were fixed in 10% buffered formalin for at least 24 h, progressively dehydrated in solutions containing an increasing percentage of ethanol (70, 80, 95, and 100%, v/v), embedded in paraffin under vacuum, sectioned at 5 µm thickness, de-paraffinized, and stained with hematoxylin-eosin (HE) and Szekely (Sz).

The tested topical oil preparation was formulated as a mixture of natural oils (olive oil - *Oleum olivarium*, linseed oil - *Oleum lini*, corn oil - *Oleum maydis*, sea buckthorn oil - *Oleum Hippophaë*, grape seed oil).

RESULTS AND DISCUSSIONS

Clinical and macroscopic results

The macroscopic evaluation of the cutaneous erythema for the 2 experimental groups (non-treated group and oil preparation group) demonstrates the efficacy of the topical oil preparation treatment. The complete healing occurred after 7 days of treatment, and evident clinical improvements were obtained even from the third day of treatment (table 1, table 2).

Table 1

Macroscopic evaluation of the cutaneous erythema

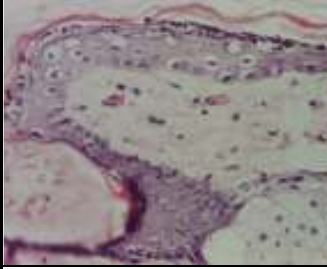
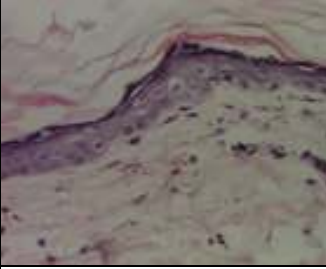
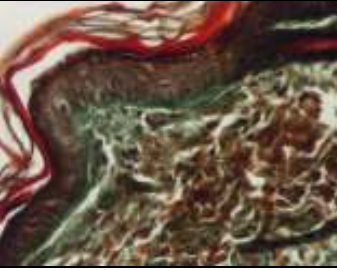
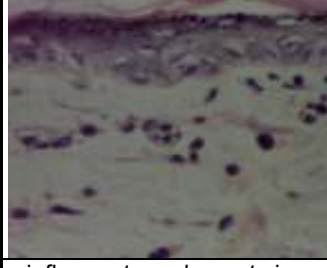
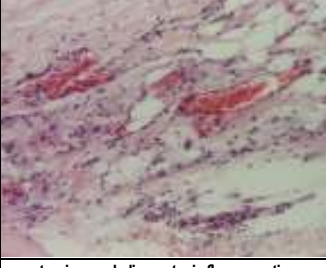
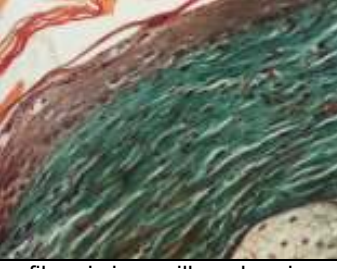
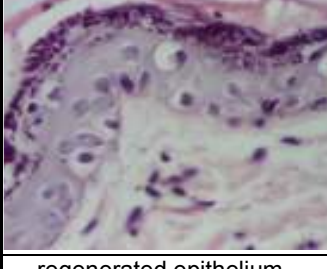
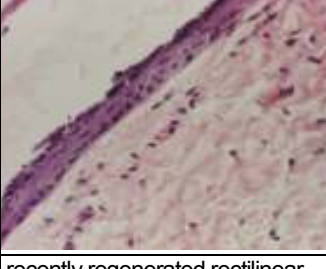
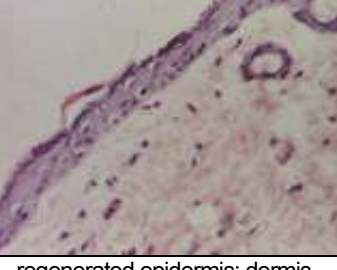
Experimental groups	Day 0	Day 2	Day 3	Day 4	Day 5	Day 7
Non-treated group						
Oil preparation group						

Histopathological results

The epidermis is intact, rectilinear, with orthokeratosis, without dermal papillae. No exocytosis or spongiosis is present. The epidermis is represented by 1-2 cell layers (non-treated group) or 2-3 cell layers: basal layer, spinous layer, granular or cornified layer (oil preparation group). In areas with 1-2 layers, the cells are small, basophilic, with hyperchrome nuclei having a slightly increased volume and frequently with an irregular contour – aspects that certify the recent regeneration of the epithelium. In areas with 2-3 layers, there can be seen vacuolar degeneration, aspects of “koilocytes” (large cells with small nuclei, moderately hyperchrome, with perinuclear halo) or aspects of large pale vesiculous nuclei, with finely dispersed chromatin and abundant cytoplasm. These cytonuclear aspects are remarked in oil preparation group, suggesting recent regeneration (table 2). For the non-treated group the basal membrane of the epidermis shows rarely and isolated a slight accentuation (table 2), and the papillary dermis shows a severe densification by collagenization, with a discrete

expression in the reticular dermis (table 3). For the oil preparation group, the aspects of collagenization are very discrete in the papillary dermis, while in the reticular dermis no signs of collagenization are seen (table 3). For the oil preparation group, the normal aspect of all the 3 layers of the dermis prevails, and the lymphocytes are minimal, in normal range. Discrete edema is remarked in the papillary dermis, with the absence of edema in the reticular dermis for the oil preparation group, while for the non-treated group, edema is present in both layers of the dermis (tables 2 and 3). The aspects of congestion are minimal to moderate, mainly for the non-treated group (table 2). The small capillaries are dilated, filled with normal erythrocytes. Haemorrhage through erythro diapedesis is present only isolated, only for the non-treated group (table 2).

Table 2

Histopathological examination		
MICROGRAPHIES		
Non-treated group		
		
vacuolar degeneration in epidermis (HEEx200)	moderate edema at the level of dermis (HEEx200)	slight accentuation of the basement membrane (Sz x 200)
		
inflammatory elements in papillary dermis (HEEx400)	stasis and discrete inflammation in hypodermis (HEEx100)	fibrosis in papillary dermis (Sz x200)
Oil preparation group		
		
regenerated epithelium (HEEx400)	recently regenerated rectilinear epidermis (HEEx200)	regenerated epidermis; dermis with discrete edema (HEEx200)

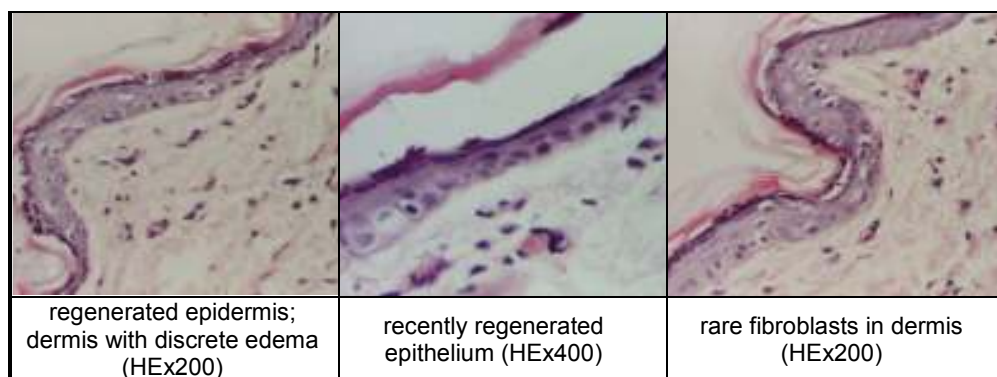


Table 3

Collagenization and intensity of edema for the 2 experimental groups

Groups	Collagenization		Edema	
	Papillary dermis	Reticular dermis	Papillary dermis	Reticular dermis
Non-treated gr	++	+/-	+	+
Oil prep gr	+/-	-	+	-

(evaluation scale of collagenization/edema: - absent, +/-discrete, + moderate, ++ severe)

Fats are indispensable for life not only as energy sources, but also for their structural role at the level of the skin, retina, nervous system, lipoproteins and biological membranes (Viola et Viola, 2009).

The oils used in this study were chosen taking into consideration the biocompatibility concept, by this understanding not only the tolerance, but also the affinity for the biological compounds at the level of the skin. The selection of olive oil was done due to the presence of 3 compounds: squalene, β -sitosterol, and α -tocopherol. The squalene exerts antioxidant effects at the cutaneous level against the damage of the solar radiations, behaving as a biological filter of the singlet oxygen (Kohn et al., 1995). Squalene is found in the unsaponifiable fraction of the olive oil, having a composition similar to that of the sebum. Squalene acts as a powerful scavenger of the singlet oxygen by inhibiting the UVA induced lipid peroxidation (Kohn et al., 1995). β -Sitosterol is a phytosterol with a sebum regulation effect (Castellani et Zumiani, 2000). Regarding the third compound, it has been observed that, after 30 minutes of UV exposure, the level of α -tocopherol in the skin is reduced to 50-60%. The topical application of α -tocopherol significantly reduces the loss (Tavakkol et al., 2004). Vitamin E from the corn oil improves the blood flow in the peripheral tissues, thus influencing positively the skin regeneration (Cosmovici et al., 1980). The sea buckthorn oil exerts antibacterial and anti-inflammatory effects (Grigorescu et al., 2001), while linseed oil possesses antibacterial activity (Kaithwas et al., 2011) and the capacity to form a protective film. The grapeseed oil, through its content of linoleic acid higher than in any other oil (Ghisalberti, 2001), determines the rapid absorption through the skin and reduces the water loss from the epidermis (Trans Epidermal

Water Loss – TEWL), thus having as effect the re-establishment of the skin elasticity (Merică, 2003). Furthermore, the conjugated linoleic acid (CLA) is an efficient agent that inhibits the skin cancer (Ghisalberti, 2001).

In the present study there have been obtained important results from the clinical point of view, with evident improvements starting from the third day of treatment, and with the complete remission of the cutaneous erythema after 7 days of treatment. Moreover, the histopathological results emphasize the efficacy of the tested oil preparation upon the chemically induced erythema.

CONCLUSIONS

The oil preparation tested in the present study proves to be efficient in the treatment of the cutaneous erythema, and the positive clinical and histopathological results open the way to new natural, biocompatible formulations based on the tested mixture of oils.

***Acknowledgments:** This paper was supported by the project PERFORM-ERA "Postdoctoral Performance for Integration in the European Research Area" (ID-57649), financed by the European Social Fund and the Romanian Government.*

REFERENCES

1. Ardelean A., Mohan G., 2008 - *Flora medicinală a României*. Editura ALL, București, p. 148-149.
2. Braha S.L., 1998 - *Elemente de dermatologie și cosmetologie*. Editura Cermi, Iași, p. 213
3. Castellani L., Zumiani G., 2000 - *L'oleosità cutanea*. La Pelle, 8, p. 41-43.
4. Cosmovici L., Samborschi E., Zisu L., 1980 - *Cosmetica. Știință – artă – frumusețe*. Editura Medicală, București, p.157.
5. Fabiani R., De Bartolomeo A., Rosignoli P., Servili M., Montedoro G.F., Morozzi G., 2002 - *Cancer chemoprevention by hydroxytyrosol isolated from virgin olive oil through G1 cell cycle arrest and apoptosis*. Eur. J. Cancer Prev., 11(4), p. 351-358.
6. Ghisalberti C., 2001 - PCT International Application WO 2001018161 A2.
7. Grigorescu E., Lazăr M.I., Stănescu U.H., Ciulei I., 2001 - *Index fitoterapeutic*. Editura Cantes, Iași, p. 349-350.
8. Ichihashi M., Ueda M., Budiyo A., Bito T., Oka M., Fukunaga M., Tsuru K., Horikawa T., 2003 - *UV-induced skin damage*. Toxicology, 189(1-2), p. 21-39.
9. Istudor V., 1998 - *Farmacognozie. Fitochimie. Fitoterapie*. Editura Medicală, București.
10. Kaithwas G., Mukerjee A., Kumar P., Majumdar D.K., 2011 - *Linum usitatissimum (linseed/flaxseed) fixed oil: antimicrobial activity and efficacy in bovine mastitis*. Inflammopharmacol, 19(1), p. 45–52.
11. Kohno Y., Egawa S., Itoh S., Nagaoka S., Takahashi M., Mukai K., 1995 - *Kinetic study of quenching reaction of singlet oxygen and scavenging reaction of free radical by squalene in n butanol*. Biochim Biophys Acta, 1256(1), p. 52-56.
12. Merică E., 2003 - *Tehnologia produselor cosmetice*. Editura Kolos, Iași, p. 57-58, 179-180.
13. Tavakkol A., Nabi Z., Soliman N., Polefka T.G., 2004 - *Delivery of vitamin E to the skin by a novel liquid cleaner: comparison of topical versus oral supplementation*. J Cosmetic Sci, 55(2), p. 177-187.
14. Viola P., Viola M., 2009 - *Virgin olive oil as a fundamental nutritional component and skin protector*. Clin Dermatol, 27, p. 159–165.